

本文章已註冊DOI數位物件識別碼

▶ Hyperammonemic Encephalopathy in Colorectal Cancer Patients Undergoing Chemotherapy

大腸直腸癌病人化學治療後的高血氨性腦病變之案例分析

doi:10.6312/SCRSTW.2013.24(1).10110

中華民國大腸直腸外科醫學會雜誌, 24(1), 2013

作者/Author：張譽耀(Yu-Yao Chang);林楨國(Jen-Kou Lin);林資琛(Tzu-Chen Lin);陳維熊(Wei-Shone Chen);楊純豪(Shung-Haur Yang);王煥昇(Huann-Sheng Wang);張世慶(Shih-Ching Chang);藍苑慈(Yuan-Tzu Lan);林春吉(Chun-Chi Lin);姜正愷(Jeng-Kai Jiang)

頁數/Page：14-20

出版日期/Publication Date：2013/03

引用本篇文獻時，請提供DOI資訊，並透過DOI永久網址取得最正確的書目資訊。

To cite this Article, please include the DOI name in your reference data.

請使用本篇文獻DOI永久網址進行連結:

To link to this Article:

[http://dx.doi.org/10.6312/SCRSTW.2013.24\(1\).10110](http://dx.doi.org/10.6312/SCRSTW.2013.24(1).10110)



DOI Enhanced

DOI是數位物件識別碼 (Digital Object Identifier, DOI) 的簡稱，是這篇文章在網路上的唯一識別碼，用於永久連結及引用該篇文章。

若想得知更多DOI使用資訊，

請參考 <http://doi.airiti.com>

For more information,

Please see: <http://doi.airiti.com>

請往下捲動至下一頁，開始閱讀本篇文獻

PLEASE SCROLL DOWN FOR ARTICLE



Case Analysis

Hyperammonemic Encephalopathy in Colorectal Cancer Patients Undergoing Chemotherapy

Yu-Yao Chang^{1,2}
Jen-Kou Lin^{1,2}
Tzu-Chen Lin^{1,2}
Wei-Shone Chen^{1,2}
Shung-Haur Yang^{1,2}
Huann-Sheng Wang^{1,2}
Shih-Ching Chang^{1,2}
Yuan-Tzu Lan^{1,2}
Chun-Chi Lin^{1,2}
Jeng-Kai Jiang^{1,2}

¹Division of Colon and Rectal Surgery,
Department of Surgery, Taipei Veterans
General Hospital,

²Department of Surgery, School of Medicine,
National Yang-Ming University, Taipei,
Taiwan

Key Words

Hyperammonemic encephalopathy;
Colorectal cancer;
Chemotherapy

Purpose. Hyperammonemic encephalopathy is an uncommon complication of chemotherapy in patients with colorectal cancer. This study describes the clinical features of hyperammonemic encephalopathy in patients who had colorectal cancer and were undergoing chemotherapy.

Methods. Data were obtained retrospectively from a prospectively collected database of colorectal malignancies at Taipei Veterans General Hospital. During 2000-2011, 6740 patients were diagnosed with colorectal malignant tumors, and 11 hyperammonemic encephalopathy events occurred in 10 of these patients. These 10 patients were finally included in the study; of these, 3 (30%) had stage III and 7 (70%) had stage IV disease.

Results: The patients (men, 6; women, 4) had primary rectal (n = 3) and colon (n = 7) tumors. The mean ammonia level was 233.5 ± 110.0 mmol/L (range: 64.3-369.0 mmol/L). The follow-up mean ammonia level at 24 hours was 42.6 ± 16.3 mmol/L (range: 17.9-66.7 mmol/L). After the patients developed hyperammonemic encephalopathy, 3 (30%) completed the full intravenous chemotherapy course, 3 (30%) reduced their dosage, and 3 (30%) shifted to oral chemotherapy; chemotherapy was stopped for 1 (10%) patient. One patient experienced recurrent hyperammonemic encephalopathy following chemotherapy (11.1%).

Conclusion. The etiology of hyperammonemic encephalopathy has not been previously clarified and was not related to the hepatitis profile or liver function in this study. Recovery from hyperammonemic encephalopathy was complete in most patients. Rechallenge with the same regimen should be safe in most cases.

[J Soc Colon Rectal Surgeon (Taiwan) 2013;24:14-20]

Five-fluorouracil (5-FU)-based chemotherapy is the standard treatment for Stage III¹ and Stage IV² colorectal carcinoma. In the 2000s, it was reported that treatment with oxaliplatin³⁻⁶ and irinotecan^{5,6} significantly prolongs the survival of and provides significant benefits to patients with colorectal cancer. However, adverse effects from chemotherapy, includ-

ing nausea, vomiting, alopecia, stomatitis, anorexia, myelotoxicity, diarrhea, and nephrotoxicity, are frequently reported in such cases.^{7,8} Peripheral neurotoxicity in patients receiving oxaliplatin is not uncommon.^{8,9} Some rare adverse effects have also been reported, including hyperammonemia,¹⁰⁻¹⁵ cardiotoxicity,¹⁶ coronary spasms,¹⁷ and central neurotoxicity.¹⁸

Received: April 18, 2012.

Accepted: August 3, 2012.

Correspondence to: Dr. Jeng-Kai Jiang, Division of Colon & Rectal Surgery, Department of Surgery, Taipei Veterans General Hospital, No. 201, Sec. 2, Shih-Pai Rd., Taipei 11217, Taiwan. Tel: +886-2-2875-7544, Fax: +886-2-2875-7639; E-mail: jkjiang@vghtpe.gov.tw

In this retrospective study, we reviewed chemotherapy-related hyperammonemic encephalopathy (HE) in patients with colorectal cancer at our hospital.

Materials and Methods

Between January 2000 and December 2011, 6740 patients were diagnosed with colorectal cancer at Taipei Veterans General Hospital. The study group was identified from a computerized database by tracking the International Classification of Diseases, 9th Revision, clinical modification¹⁹ code (ICD-9-CM). The patients were enrolled if their ICD-9-CM code included 153 or 154 (colon or rectal cancer) and 348 or 349 (encephalopathy). Patients who had hypoxic encephalopathy, alcoholic encephalopathy, or hepatic encephalopathy were excluded from this study.

Information including age, gender, tumor location, tumor staging (TNM, 6th American Joint Committee on Cancer system),²⁰ and clinical follow-up were obtained from extensive chart review. In these patients, the presurgical events consisted of physical examination, complete blood count (CBC), chemical profile, chest radiography, and a computed tomography scan. Data pertaining to the viral hepatitis markers, including hepatitis B virus surface antigen (HBsAg), anti-hepatitis B surface antibody (anti-HBs Ab), and anti-hepatitis C antibody (anti-HCV Ab), were also recorded. HBsAg and anti-HBs Ab levels were analyzed using radioimmunoassays (RIAs), while anti-HCV Ab levels were analyzed using enzyme-linked immunosorbent assays (ELISAs). The performance status of these patients was assessed using the Eastern Cooperative Oncology Group (ECOG) score.²¹ All the patients were postoperatively followed up at 3-month intervals for the first 2 years, 6-month intervals for years 3-5, and annually thereafter.

Hyperammonemia was defined as a serum ammonia level higher than 41 mmol/L. HE was defined as the presence of hyperammonemia and altered consciousness. The level of ammonia was recorded immediately after HE occurred. The regimen, dosage, and chemotherapy cycle at this time point were also identified. All patients with HE were treated with intravenous hydration and lactulose solution, either in

oral form or via enema. The ammonia level was recorded again 24 hours later.

Results

A total of 15 patients (age, 31-86) developed encephalopathy. Three patients with hypoxic encephalopathy that was not related to hyperammonemia were excluded from the study. Among the 12 patients with HE, 2 were excluded because of missing medical records. Finally, 10 patients with 11 episodes of HE were included in the study. A diagram describing the patients has been provided in Fig. 1.

The clinical features of the patients with HE are listed in Table 1. The study population included 6 men (60%) and 4 women (40%). Tumors were located in the ascending colon (n = 1), transverse colon (n = 1), splenic flexure (n = 1), descending colon (n = 1), sigmoid colon (n = 3), and rectum (n = 3). Three patients (30%) had stage III disease and the other 7 patients (70%) had stage IV disease. Among the 7 patients with stage IV disease, 5 (71.4%) had solitary liver metastasis, 1 (14.3%) had lung metastasis, and 1 (14.3%) had liver, brain, and lung metastases. None of the

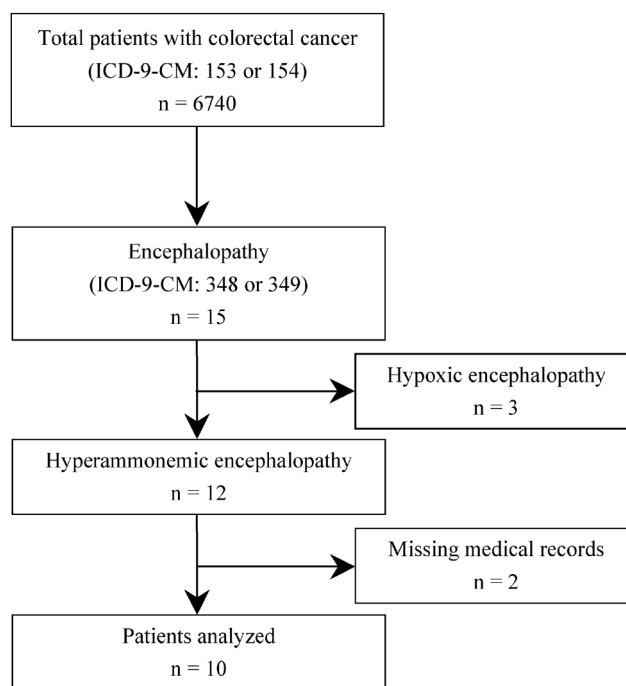


Fig. 1. Diagram outlining data for the patients involved in the study.

Table 1. Clinical features of patients with hyperammonemic encephalopathy

Event	Patient	Age/ Gender	Tumor Location	Stage ^{a,b}	Surgical Intervention	Metastasis ^b	HBsAg	Anti-HBs Ab	Anti-HCV Ab	AST (U/L)	ALT (U/L)	Total Bilirubin (mg/dL)	Na (mmol/L)	K (mmol/L)
1	1	86/F	Sigmoid colon	III	AR	Nil	Negative	NA	Negative	29	13	0.29	139	3.2
2	2	62/M	Rectum	IV	LAR	Lung	NA	NA	NA	60	38	1.1	133	4.2
3	3	61/F	Rectum	IV	LAR	Liver, Brain, Lung	Negative	NA	Negative	20	17	0.12	137	3.5
4	4	73/F	Ascending colon	III	RH	Nil	Negative	Positive	Negative	27	22	0.8	133	3.8
5	5	70/F	Rectum	IV	LAR	Liver	Negative	Negative	Negative	26	17	0.75	135	3.4
6	6	69/M	Descending colon	III	LH	Nil	Negative	Positive	Negative	21	30	0.77	132	4.2
7	7	31/M	Sigmoid colon	IV	AR	Liver	NA	NA	NA	14	15	0.4	134	4.2
8	8	76/M	Sigmoid colon	IV	AR	Liver	Negative	Positive	Negative	48	30	0.96	140	4.5
9	8	76/M	Sigmoid colon	IV	AR	Liver	Negative	Positive	Negative	51	32	0.83	142	3.9
10	9	64/M	Transverse colon	IV	RH	Liver	Negative	Positive	Negative	69	54	0.53	140	3.6
11	10	73/M	Splenic flexure	IV	LH	Liver	Negative	NA	NA	35	17	0.5	137	4.7

F: female; M: male; LAR: low anterior resection; LH: left hemicolectomy; AR: anterior resection; RH: right hemicolectomy; AST: Aspartate transaminase; ALT: Alanine transaminase; HBsAg: hepatitis B virus surface antigen; anti-HBs Ab: anti-hepatitis B surface antibody; anti-HCV Ab: anti-hepatitis C antibody; NA: not available.

^a Stage groupings according to the AJCC and UICC system for cancer of the colon and rectum, 6th edition.

^b Indicates the status when hyperammonemic encephalopathy occurred

hepatitis profiles showed evidence of HBV or HCV infection. An ECOG score of 1 was obtained for 5 patients, and a score of 2 was obtained for the other 5 patients. The levels of aspartate transaminase and alanine transaminase were within normal limits or were mildly elevated. The levels of total bilirubin were within normal limits. There was no significant electrolyte imbalance. No evidence of liver cirrhosis was seen on liver sonography before and after HE. No episodes of gastrointestinal bleeding were recorded.

The chemotherapy regimen and ammonia levels of the patients with HE are listed in Table 2. Among the 11 events of HE, 5 (45.5%) were associated with the FOLFOX6 regimen, 5 (45.5%) were associated with the FOLFOX4 regimen, and 1 (9%) was associated with the HDFL (high dose 5-FU and leucovorin) regimen. Ten events (90.9%) were induced by 5-FU and 1 (9.1%) by oxaliplatin. The median cycle number when HE developed was 3. Most of the patients regained consciousness 1 day later; however, 1 patient

remained in a permanent vegetative state after hypoxic encephalopathy resulting from HE. The mean ammonia level was 233.5 ± 110.0 mmol/L (range: 64.3-369.0 mmol/L). The mean follow-up ammonia level at 24 hours was 42.6 ± 16.3 mmol/L (range: 17.9-66.7 mmol/L).

After the patients developed HE, 3 (30%) completed their entire intravenous chemotherapy course (Table 2), 3 (30%) reduced their chemotherapy dosage, 2 (20%) shifted to oral chemotherapy with Ufur[®] (tegafur and uracil), and 1 (10%) shifted to Xeloda[®] (capecitabine) and oxaliplatin. Chemotherapy was discontinued for the patient (10%) who was in a vegetative state. Among the patients who received full-dose intravenous chemotherapy or oral chemotherapy, there was no recurrent episode of HE. Only patient 8, who received two-thirds the doses normally administered in the FOLFOX6 regimen after the first episode of HE, experienced recurrent HE.

The median follow-up in these patients was 12.0

Table 2. Chemotherapy regimen and ammonia levels of patients with hyperammonemic encephalopathy

Event	Patient	Regimen	Cycle	Drug inducing HE	Ammonia level (mmol/L)	Follow-up ammonia level at 24 h (mmol/L)	Regained consciousness (day)	Further treatment for cancer	Current status
1	1	FOLFOX4	1	Fluorouracil	268.5	48.2	1	1/2 FOLFOX4	Alive without disease
2	2	FOLFOX4	1	Fluorouracil	271.4	57.1	1	XELOX	Died of disease
3	3	FOLFOX6	2	Fluorouracil	331.5	47.6	1	1/3 FOLFOX6	Died of disease
4	4	FOLFOX4	2	Fluorouracil	341.7	39.3	1	Ufur	Alive without disease
5	5	FOLFOX6	3	Fluorouracil	369.0	NA	1	Full FOLFOX6	Died of disease
6	6	HDFL	3	Fluorouracil	349.4	17.9	1	Ufur	Alive without disease
7	7	FOLFOX4	3	Fluorouracil	179.2	NA	1	Full FOLFOX4	Died of disease
8	8	FOLFOX6	4	Fluorouracil	145.2	40.5	2	2/3 FOLFOX6	Died of disease
9	8	FOLFOX6	5	Fluorouracil	154.8	66.7	2	1/2 FOLFOX6	Died of disease
10	9	FOLFOX4	5	Oxaliplatin	93.5	23.2	none	Nil	Alive with disease, comatose state
11	10	FOLFOX6	7	Fluorouracil	64.3	NA	1	Full FOLFOX6	Died of disease

HE: Hyperammonemic encephalopathy; NA: not available.

months (range: 4.8-54.8 months). Six patients (60%) died of colorectal cancer, 3 (30%) were alive without disease, and 1 (10%) was alive with liver metastasis. The last patient received supportive treatment only because of the vegetative state.

None of the patients with stage III disease died. The median survival in patients with stage IV disease was 12.5 months.

Discussion

HE is an uncommon but frequently fatal complication of chemotherapy for malignancies including hematological malignancies²² and solid tumors.^{10-12,14,15} It has also been reported after bone marrow transplant in patients with hematological malignancies.^{23,24} Chemotherapeutic agents reported to be associated with HE include rituximab,¹³ 5-FU,^{14,15} cytarabine, vincristine, amsacrine, etoposide, L-asparaginase, and cyclophosphamide, used in various combinations.¹²

The clinical manifestations of hyperammonemia range from mild to severe encephalopathy, including disorientation, confusion, agitation, neurosensory hearing impairment, seizure, stupor, and deep coma. Hyperammonemia, lactic acidosis, hyperammonemia-induced hypocapnia and mild-to-moderate elevation of liver transaminases have been reported in most patients who received 5-FU and developed encephalopathy.

Yeh et al. reported severe manifestations of HE in 13 of 16 patients and, in 2 of the 13 patients, these symptoms were combined with seizures.¹⁰ In our study, all 10 patients developed deep coma but none of them had seizures.

The etiology of HE is not clear and is generally considered multifactorial. Formica et al. hypothesized that the drug itself, or the metabolite, crosses the blood-brain barrier.²⁵ Koenig et al. postulated that the intermediate product of 5-FU metabolism inhibits the Krebs tricarboxylic acid cycle, which in turn causes impairment of the adenosine triphosphate-dependent urea cycle, resulting in hyperammonemia.²⁶ Accumulation of ammonia in the brain results in redistribution of cerebral blood flow and metabolism from cortical to subcortical structures. In addition, hyperammonemia results in alterations in astrocytic volume and increase in the extracellular concentrations of excitatory and inhibitory substances.²⁷ Hyperammonemia may cause cerebral edema, altered mental status, seizures, coma, or death.

Among the 11 episodes of HE, 10 were induced by 5-FU, while 1 was induced by oxaliplatin. The latter case was, to our knowledge, the first report of oxaliplatin-induced HE.²⁸ The patient was undergoing the fifth cycle of FOLFOX4. However, at the time of HE occurrence, he was undergoing oxaliplatin infusion, and 5-FU or folinic acid infusion had not been initiated. Therefore, the possibility of 5-FU-induced

HE was excluded. In 2 of the 10 episodes of 5-FU-induced HE, HE occurred when the patients were exposed to 5-FU for the first time, while in the other 8 episodes, HE occurred in the first half of the cycles.

For most patients, the plasma ammonium levels and mental status returned to normal within 2 days after adequate management.¹¹ Shoji et al. reported the case of a patient who had metastatic colorectal cancer and developed 5-FU-induced HE, wherein the symptoms entirely disappeared on day 4.¹⁴ Yeh et al. reported a case of 5-FU-induced HE where the patient was in a coma for 40 hours.²⁹ In our study, 8 of the 11 patients with HE regained consciousness within 24 hours, while the patient who had recurrent HE recovered between 24 and 48 hours. The patient with oxaliplatin-induced HE developed prolonged hypoxia due to delayed airway intubation and never regained his consciousness.

Survival in patients who developed chemotherapy-induced HE has not been discussed in the literature. Because the incidence was low, in our study, there was no mortality in patients with stage III disease. De Gramont et al reported that median survival in patients with stage IV disease undergoing chemotherapy with FOLFOX4 was 16.2 months.³ In our study, the median survival in patients with stage IV disease was 12.5 months. The reason for this difference could be that some patients in our study reduced their dosage of chemotherapy or shifted to oral chemotherapy after HE, which may worsen prognosis.

In a previous study, after the patients recovered from 5-FU-induced HE, they successfully restarted chemotherapy involving capecitabine¹⁵ and 5-FU.¹⁴ In our study, most patients restarted chemotherapy after they recovered from HE. Six patients received the same regimen, with either full dose or reduced dose, and there was 1 episode of recurrent HE. The only patient who had recurrent HE then received half the dosage of the same regimen in the following chemotherapy cycle and, interestingly, HE did not recur. For those who shifted to oral chemotherapy, no recurrent episodes of HE were noted. While the etiology of HE is multifactorial, it might correlate not only with the chemotherapy regimen but also with performance status and the physiological status of the patient. Therefore, we suggest that patients should continue the

same chemotherapy regimen at full dose after complete recovery from HE. Should recurrent HE develop, the patient might reduce the dosage or shift to oral chemotherapy.

Conclusion

Hyperammonemic encephalopathy is an uncommon complication of chemotherapy in patients with colorectal cancer but can be fatal. The etiology of hyperammonemic encephalopathy was not clarified and was not related to the hepatitis profile or liver function. Recovery from hyperammonemic encephalopathy was complete in most patients. Rechallenge with the same regimen should be safe in most cases.

References

1. Efficacy of adjuvant fluorouracil and folinic acid in colon cancer. International Multicentre Pooled Analysis of Colon Cancer Trials (IMPACT) investigators. *Lancet* 1995;345: 939-44.
2. Simpson D, Dunn C, Curran M, Goa KL. Oxaliplatin: a review of its use in combination therapy for advanced metastatic colorectal cancer. *Drugs* 2003;63:2127-56.
3. de Gramont A, Figer A, Seymour M, Homerin M, Hmissi A, Cassidy J, Boni C, Cortes-Funes H, Cervantes A, Freyer G, Papamichael D, Le Bail N, Louvet C, Hendler D, de Braud F, Wilson C, Morvan F, Bonetti A. Leucovorin and fluorouracil with or without oxaliplatin as first-line treatment in advanced colorectal cancer. *J Clin Oncol* 2000;18:2938-47.
4. Andre T, Boni C, Mounedji-Boudiaf L, Navarro M, Tabernero J, Hickish T, Topham C, Zaninelli M, Clingan P, Bridgewater J, Tabah-Fisch I, de Gramont A. Oxaliplatin, fluorouracil, and leucovorin as adjuvant treatment for colon cancer. *N Engl J Med* 2004;350:2343-51.
5. Goldberg RM, Sargent DJ, Morton RF, Fuchs CS, Ramanathan RK, Williamson SK, Findlay BP, Pitot HC, Alberts SR. A randomized controlled trial of fluorouracil plus leucovorin, irinotecan, and oxaliplatin combinations in patients with previously untreated metastatic colorectal cancer. *J Clin Oncol* 2004;22:23-30.
6. Tournigand C, Andre T, Achille E, Lledo G, Flesh M, Mery-Mignard D, Quinaux E, Couteau C, Buyse M, Ganem G, Landi B, Colin P, Louvet C, de Gramont A. FOLFIRI followed by FOLFOX6 or the reverse sequence in advanced colorectal cancer: a randomized GERCOR study. *J Clin Oncol* 2004;22:229-37.
7. Macdonald JS. Toxicity of 5-fluorouracil. *Oncology (Wil-*

- liston Park) 1999;13:33-4.
8. Cassidy J, Misset JL. Oxaliplatin-related side effects: characteristics and management. *Semin Oncol* 2002;29:11-20.
 9. Gamelin E, Gamelin L, Bossi L, Quasthoff S. Clinical aspects and molecular basis of oxaliplatin neurotoxicity: current management and development of preventive measures. *Semin Oncol* 2002;29:21-33.
 10. Yeh KH, Cheng AL. High-dose 5-fluorouracil infusional therapy is associated with hyperammonaemia, lactic acidosis and encephalopathy. *Br J Cancer* 1997;75:464-5.
 11. Liaw CC, Wang HM, Wang CH, Yang TS, Chen JS, Chang HK, Lin YC, Liaw SJ, Yeh CT. Risk of transient hyperammonemic encephalopathy in cancer patients who received continuous infusion of 5-fluorouracil with the complication of dehydration and infection. *Anticancer Drugs* 1999;10:275-81.
 12. Nott L, Price TJ, Pittman K, Patterson K, Fletcher J. Hyperammonemia encephalopathy: an important cause of neurological deterioration following chemotherapy. *Leuk Lymphoma* 2007;48:1702-11.
 13. Nott L, Price TJ, Pittman K, Patterson K, Young R, Fletcher J. Hyperammonaemic encephalopathy associated with rituximab-containing chemotherapy. *Intern Med J* 2008;38:800-3.
 14. Shoji H, Kuroki M, Hiramoto K, Matsumura Y, Miura A, Kikuchi Y, Hirakawa H. A case of metastatic colorectal cancer suffering from hyperammonemic encephalopathy induced by 5-FU, continuously treated with FOLFOX therapy. *Gan To Kagaku Ryoho* 2010;37:1583-6.
 15. Advani PP, Fakih MG. 5-FU-induced hyperammonemic encephalopathy in a case of metastatic rectal adenocarcinoid successfully rechallenged with the fluoropyrimidine analog, capecitabine. *Anticancer Res* 2011;31:335-8.
 16. Lukaschek J, Nufer M, Maurer D, Asanger M, Honegger H, Widmer L, Malet-Martino M, Legay R, Martino R. Cardiotoxicity and neurotoxicity of high-dose continuous fluorouracil as a result of degradation compounds in the drug vials. *J Clin Oncol* 2004;22:5022-5.
 17. Arbea L, Coma-Canella I, Martinez-Monge R, Garcia-Foncillas J. A case of capecitabine-induced coronary microspasm in a patient with rectal cancer. *World J Gastroenterol* 2007;13:2135-7.
 18. Sioka C, Kyritsis AP. Central and peripheral nervous system toxicity of common chemotherapeutic agents. *Cancer Chemother Pharmacol* 2009;63:761-7.
 19. International Classification of Diseases, Ninth Revision, Clinical Modification (ICD-9-CM). *Centers of Disease Control and Prevention* 2011.
 20. Greene FL PD, Fleming ID, Fritz AG, Balch CM, Haller DG, Morrow M. *AJCC Cancer Staging Manual* (6th ed). Chicago, IL, Springer 2002.
 21. Oken MM, Creech RH, Tormey DC, Horton J, Davis TE, McFadden ET, Carbone PP. Toxicity and response criteria of the Eastern Cooperative Oncology Group. *Am J Clin Oncol* 1982;5:649-55.
 22. Howman R, Thakerer A, Pitman M, Ding N, Thompson PA, Khot A, Harrison SJ. Bortezomib, cyclophosphamide, and dexamethasone: highly effective for rapid reversal of myeloma-associated hyperammonemic encephalopathy. *Leuk Lymphoma* 2010;51:2299-302.
 23. Tse N, Cederbaum S, Glaspy JA. Hyperammonemia following allogeneic bone marrow transplantation. *Am J Hematol* 1991;38:140-1.
 24. Ho AY, Mijovic A, Pagliuca A, Mufti GJ. Idiopathic hyperammonaemia syndrome following allogeneic peripheral blood progenitor cell transplantation (allo-PBPCT). *Bone Marrow Transplant* 1997;20:1007-8.
 25. Formica V, Leary A, Cunningham D, Chua YJ. 5-Fluorouracil can cross brain-blood barrier and cause encephalopathy: should we expect the same from capecitabine? A case report on capecitabine-induced central neurotoxicity progressing to coma. *Cancer Chemother Pharmacol* 2006;58:276-8.
 26. Koenig H, Patel A. Biochemical basis for fluorouracil neurotoxicity. The role of Krebs cycle inhibition by fluoroacetate. *Arch Neurol* 1970;23:155-60.
 27. Felipe V, Butterworth RF. Neurobiology of ammonia. *Prog Neurobiol* 2002;67:259-79.
 28. Chang YY, Lin JK, Jiang JK. Oxaliplatin-related hyperammonaemic encephalopathy in a patient with colon cancer. *Colorectal Dis* 2012.
 29. Yeh KH, Cheng AL. Acute confusion induced by a high-dose infusion of 5-fluorouracil and folinic acid. *J Formos Med Assoc* 1994;93:721-3.

病例分析

大腸直腸癌病人化學治療後的高血氨性腦病變之案例分析

張譽耀^{1,2} 林楨國^{1,2} 林資琛^{1,2} 陳維熊^{1,2} 楊純豪^{1,2} 王煥昇^{1,2}
張世慶^{1,2} 藍苑慈^{1,2} 林春吉^{1,2} 姜正愷^{1,2}

¹台北榮民總醫院 外科部 大腸直腸外科

²國立陽明大學

目的 高血氨性腦病變是一罕見的化學治療併發症。此篇研究是為了分析本院大腸直腸癌病人接受化學治療後的高血氨性腦病變臨床上的表現。

方法 本研究回溯收集台北榮民總醫院大腸直腸外科資料庫，於 2000 至 2011 年間，共有 6740 位診斷結腸直腸癌的病患，其中在 10 位病患上發生了 11 次高血氨性腦病變。將這些病人的臨床及病理的資料予以分析。

結果 這 10 位病患分別為 6 位男性及 4 位女性，有 7 位結腸腫瘤，3 位直腸腫瘤。平均血氨濃度為 233.5 ± 110.0 mmol/L (範圍：64.3-369.0 mmol/L)。24 小時後追蹤平均血氨濃度為 42.6 ± 16.3 mmol/L (範圍：17.9-66.7 mmol/L)。在高血氨性腦病變發生後，三位病人接受完整的靜脈化學治療，三位病人接受減低劑量的靜脈化學治療，三位病人接受口服化學治療，一位病人沒有接受任何化學治療。有一位病患產生了復發的高血氨性腦病變。

結論 高血氨性腦病變的病因不明，而且與肝炎及肝功能無關。大部分的病人可以完全康復，且繼續使用相同的藥物對大部分病人來說是安全的。

關鍵詞 高血氨性腦病變、大腸直腸癌、化學治療。